

# THE CASE AGAINST CIRCUMCISION

BY PAUL M. FLEISS

**W**estern countries have no tradition of circumcision. In antiquity, the expansion of the Greek and Roman Empires brought Westerners into contact with the peoples of the Middle East, some of whom marked their children with circumcision and other sexual mutilations. To protect these children, the Greeks and Romans passed laws forbidding circumcision.<sup>1</sup> Over the centuries, the Catholic Church has passed many similar laws.<sup>2,3</sup> The traditional Western response to circumcision has been revulsion and indignation.

Circumcision started in America during the masturbation hysteria of the Victorian Era, when a few American doctors circumcised boys to punish them for masturbating. Victorian doctors knew very well that circumcision denudes, desensitizes, and disables the penis. Nevertheless, they were soon claiming that circumcision cured epilepsy, convulsions, paralysis, elephantiasis, tuberculosis, eczema, bed-wetting, hip-joint disease, fecal incontinence, rectal prolapse, wet dreams, hernia, headaches, nervousness, hysteria, poor eyesight, idiocy, mental retardation, and insanity.<sup>4</sup>

In fact, no procedure in the history of medicine has been claimed to cure and prevent more diseases than circumcision. As late as the 1970s, leading American medical textbooks still advocated routine circumcision as a way to prevent masturbation.<sup>5</sup> The antisexual motivations behind an operation that entails cutting off part of the penis are obvious.

The radical practice of routinely circumcising babies did not begin until the Cold War era. This institutionalization of what amounted to compulsory circumcision was part of the same movement that pathologized and medicalized birth and actively discouraged breastfeeding. Private-sector, corporate-run hospitals institutionalized routine circumcision without ever consulting the American people.

There was no public debate or referendum. It was only in the 1970s that a series of lawsuits forced hospitals to obtain parental consent to perform this contraindicated but highly profitable surgery. Circumcisers responded by inventing new "medical" reasons for circumcision in an attempt to scare parents into consenting.

Today the reasons given for circumcision have been updated to play on contemporary fears and anxieties; but one day they, too, will be considered irrational. Now that such current excuses as the claim that this procedure prevents cancer and sexually transmitted diseases have been thoroughly discredited, circumcisers will undoubtedly invent new ones. But if circumcisers were really motivated by purely medical considerations, the procedure would have died out long ago, along with leeching, skull-drilling, and castration. The fact that it has not suggests that the compulsion to circumcise came first, the "reasons," later.

Millions of years of evolution have fashioned the human body into a model of refinement, elegance, and efficiency, with every part having a function and purpose. Evolution has determined that mammals' genitals should be sheathed in a protective, responsive, multipurpose foreskin. Every normal human being is born with a foreskin. In females, it protects the glans of the clitoris; in males, it protects the

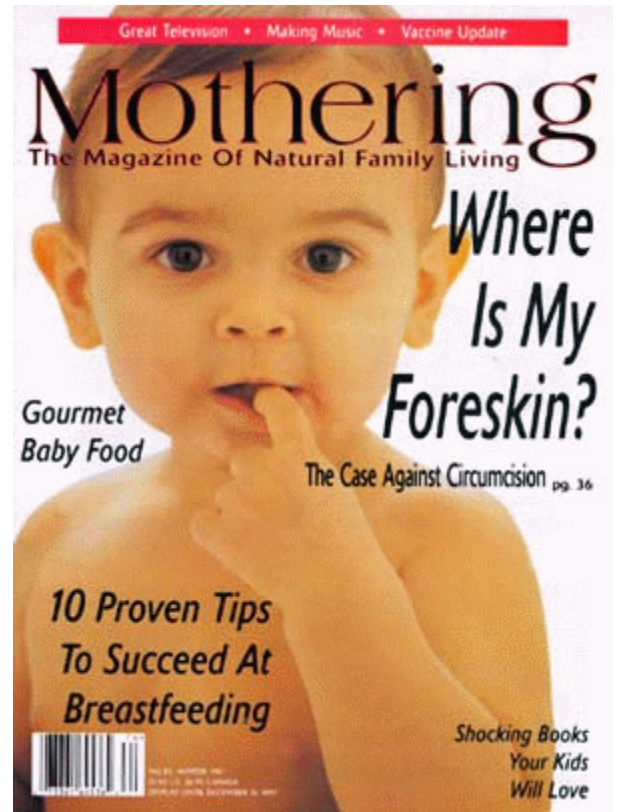
glans of the penis. Thus, the foreskin is an essential part of human sexual anatomy.

Parents should enjoy the arrival of a new child with as few worries as possible. The birth of a son in the US, however, is often fraught with anxiety and confusion. Most parents are pressured to hand their baby sons over to a stranger, who, behind closed doors, straps babies down and cuts their foreskins off. The billion-dollar-a-year circumcision industry has bombarded Americans with confusing rhetoric and calculated scare tactics.

Information about the foreskin itself is almost always missing from discussions about circumcision. The mass circumcision campaigns of the past few decades have resulted in pandemic ignorance about this remarkable structure and its versatile role in human sexuality. Ignorance and false information about the foreskin are the rule in American medical literature, education, and practice. Most American medical textbooks depict the human penis, without explanation, as circumcised, as if it were so by nature.

## What Is the Foreskin?

The foreskin is a uniquely specialized, sensitive, functional organ of touch. No other part of the body serves the same purpose. As a modified extension of the penile shaft skin, the foreskin covers and usually extends beyond the glans before



folding under itself and finding its circumferential point of attachment just behind the corona (the rim of the glans). The foreskin is, therefore, a double-layered organ. Its true length is twice the length of its external fold and comprises as much as 80 percent or more of the penile skin covering.<sup>6,7</sup>

The foreskin contains a rich concentration of blood vessels and nerve endings. It is lined with the peripenic muscle sheet, a smooth muscle layer with longitudinal fibers. These muscle fibers are whirled, forming a kind of sphincter that ensures optimum protection of the urinary tract from contaminants of all kinds.

Like the undersurface of the eyelids or the inside of the cheek, the undersurface of the foreskin consists of mucous membrane. It is divided into two distinct zones: the soft mucosa and the ridged mucosa. The soft mucosa lies against the glans penis and contains ectopic sebaceous glands that secrete emollients, lubricants, and protective antibodies. Similar glands are found in the eyelids and mouth.

Adjacent to the soft mucosa and just behind the lips of the foreskin is the ridged mucosa. This exquisitely sensitive structure consists of tightly pleated concentric bands, like the elastic bands at the top of a sock. These expandable pleats allow the foreskin lips to open and roll back, exposing the glans. The ridged mucosa gives the foreskin its characteristic taper.

On the underside of the glans, the foreskin's point of attachment is advanced toward the meatus (urethral opening) and forms a bandlike ligament called the frenulum. It is identical to the frenulum that secures the tongue to the floor of the mouth. The foreskin's frenulum holds it in place over the glans, and, in conjunction with the smooth muscle fibers, helps return the retracted foreskin to its usual forward position over the glans.

### Retraction of the Foreskin

At birth, the foreskin is usually attached to the glans, very much as a fingernail is attached to a finger. By puberty, the penis will usually have completed its development, and the foreskin will have separated from the glans.<sup>8</sup> This separation occurs in its own time; there is no set age by which the foreskin and glans must be separated. One wise doctor described the process thus, "The foreskin therefore can be likened to a rosebud which remains closed and muzzled. Like a rosebud, it will only

blossom when the time is right. No one opens a rosebud to make it blossom."<sup>9</sup>

Even if the glans and foreskin separate naturally in infancy, the foreskin lips can normally dilate only enough to allow the passage of urine. This ideal feature protects the glans from premature exposure to the external environment.

The penis develops naturally throughout childhood. Eventually, the child will, on his own, make the wondrous discovery that his foreskin will retract. There is no reason for parents, physicians, or other caregivers to manipulate a child's penis. The only person to retract a child's foreskin should be the child himself, when he has discovered that his foreskin is ready to retract.

Parents should be wary of anyone who tries to retract their child's foreskin, and especially wary of anyone who wants to cut it off. Human foreskins are in great demand for any number of commercial enterprises, and the marketing of purloined baby foreskins is a multimillion-dollar-a-year industry. Pharmaceutical and cosmetic companies use human foreskins as research material. Corporations such as Advanced Tissue Sciences, Organogenesis, and BioSurface Technology use human foreskins as the raw materials for a type of breathable bandage.<sup>10</sup>

### What Are the Foreskin's Functions?

The foreskin has numerous protective, sensory, and sexual functions.

- **Protection:** Just as the eyelids protect the eyes, the foreskin protects the glans and keeps its surface soft, moist, and sensitive. It also maintains optimal warmth, pH balance, and cleanliness. The glans itself contains no sebaceous glands – glands that produce the sebum, or oil, that moisturizes our skin.<sup>11</sup> The foreskin produces the sebum that maintains proper health of the surface of the glans.

- **Immunological Defense:** The mucous membranes that line all body orifices are the body's first line of immunological defense. Glands in the foreskin produce antibacterial and antiviral proteins such as lysozyme.<sup>12</sup> Lysozyme is also found in tears and mother's milk. Specialized epithelial Langerhans cells, an immune system component, abound in the foreskin's outer surface.<sup>13</sup> Plasma cells in the foreskin's mucosal lining secrete immunoglobulins, antibodies that defend against infection.<sup>14</sup>

- **Erogenous Sensitivity:** The foreskin is as sensitive as the fingertips or the lips of

the mouth. It contains a richer variety and greater concentration of specialized nerve receptors than any other part of the penis.<sup>15</sup> These specialized nerve endings can discern motion, subtle changes in temperature, and fine gradations of texture.<sup>16, 17, 18, 19, 20, 21, 22, 23</sup>

- **Coverage during Erection:** As it becomes erect, the penile shaft becomes thicker and longer. The double-layered foreskin provides the skin necessary to accommodate the expanded organ and to allow the penile skin to glide freely, smoothly, and pleurably over the shaft and glans.

- **Self-Stimulating Sexual Functions:** The foreskin's double-layered sheath enables the penile shaft skin to glide back and forth over the penile shaft. The foreskin can normally be slipped all the way, or almost all the way, back to the base of the penis, and also slipped forward beyond the glans. This wide range of motion is the mechanism by which the penis and the orgasmic triggers in the foreskin, frenulum, and glans are stimulated.

- **Sexual Functions in Intercourse:** One of the foreskin's functions is to facilitate smooth, gentle movement between the mucosal surfaces of the two partners during intercourse. The foreskin enables the penis to slip in and out of the vagina non-abrasively inside its own slick sheath of self-lubricating, movable skin. The female is thus stimulated by moving pressure rather than by friction only, as when the male's foreskin is missing.

The male's foreskin fosters intimacy between the two partners by enveloping the glans and maintaining it as an internal organ. The sexual experience is enhanced when the foreskin slips back to allow the male's internal organ, the glans, to meet the female's internal organ, the cervix – a moment of supreme intimacy and beauty.

The foreskin may have functions not yet recognized or understood. Scientists in Europe recently detected estrogen receptors in its basal epidermal cells.<sup>24</sup> Researchers at the University of Manchester found that the human foreskin has apocrine glands.<sup>25</sup> These specialized glands produce pheromones, nature's chemical messengers. Further studies are needed to fully understand these features of the foreskin and the role they play.

### Care of the Foreskin

The natural penis requires no special care. A child's foreskin, like his eyelids, is self-cleansing. For the same reason it is inad-

visible to lift the eyelids and wash the eyeballs, it is inadvisable to retract a child's foreskin and wash the glans. Immersion in plain water during the bath is all that is needed to keep the intact penis clean.<sup>26</sup>

The white emollient under the child's foreskin is called smegma. Smegma is probably the most misunderstood, most unjustifiably maligned substance in nature. Smegma is clean, not dirty, and is beneficial and necessary. It moisturizes the glans and keeps it smooth, soft, and supple. Its antibacterial and antiviral properties keep the penis clean and healthy. All mammals produce smegma. Thomas J. Ritter, MD, underscored its importance when he commented, "The animal kingdom would probably cease to exist without smegma."<sup>27</sup>

Studies suggest that it is best not to use soap on the glans or foreskin's inner fold.<sup>28</sup> Forcibly retracting and washing a baby's foreskin destroys the beneficial bacterial flora that protect the penis from harmful germs and can lead to irritation and infection. The best way to care for a child's intact penis is to leave it alone. After puberty, males can gently rinse their glans and foreskin with warm water, according to their own self-determined needs.

### How Common Is Circumcision?

Circumcision is almost unheard of in Europe, South America, and non-Muslim Asia. In fact, only 10 to 15 percent of men throughout the world are circumcised, the vast majority of whom are Muslim.<sup>29</sup> The neonatal circumcision rate in the western US has now fallen to 34.2 percent.<sup>30</sup> This relatively diminished rate may surprise American men born during the era when nearly 90 percent of baby boys were circumcised automatically, with or without their parents' consent.

### How Does Circumcision Harm?

The "medical" debate about the "potential health benefits" of circumcision rarely addresses its real effects.

- **Circumcision denudes:** Depending on the amount of skin cut off, circumcision robs a male of as much as 80 percent or more of his penile skin. Depending on the foreskin's length, cutting it off makes the penis as much as 25 percent or more shorter. Careful anatomical investigations have shown that circumcision cuts off more than 3 feet of veins, arteries, and capillaries, 240 feet of nerves, and more

than 20,000 nerve endings.<sup>31</sup> The foreskin's muscles, glands, mucous membrane, and epithelial tissue are destroyed, as well.

- **Circumcision desensitizes:** Circumcision desensitizes the penis radically. Foreskin amputation means severing the rich nerve network and all the nerve receptors in the foreskin itself. Circumcision almost always damages or destroys the frenulum. The loss of the protective foreskin desensitizes the glans. Because the membrane covering the permanently externalized glans is now subjected to constant abrasion and irritation, it keratinizes, becoming dry and tough. The nerve endings in the glans, which in the intact penis are just beneath the surface of the mucous membrane, are now buried by successive layers of keratinization. The denuded glans takes on a dull, grayish, sclerotic appearance.

- **Circumcision disables:** The amputation of so much penile skin permanently immobilizes whatever skin remains, preventing it from gliding freely over the shaft and glans. This loss of mobility destroys the mechanism by which the glans is normally stimulated. When the circumcised penis becomes erect, the immobilized remaining skin is stretched, sometimes so tightly that not enough skin is left to cover the erect shaft. Hair-bearing skin from the groin and scrotum is often pulled onto the shaft, where hair is not normally found. The surgically externalized mucous membrane of the glans has no sebaceous glands. Without the protection and emollients of the foreskin, it dries out, making it susceptible to cracking and bleeding.

- **Circumcision disfigures:** Circumcision alters the appearance of the penis drastically. It permanently externalizes the glans, normally an internal organ. Circumcision leaves a large circumferential surgical scar on the penile shaft. Because circumcision usually necessitates tearing the foreskin from the glans, pieces of the glans may be torn off, too, leaving it pitted and scarred. Shreds of foreskin may adhere to the raw glans, forming tags and bridges of dangling, displaced skin.<sup>32</sup>

Depending on the amount of skin cut off and how the scar forms, the circumcised penis may be permanently twisted, or curve or bow during erection.<sup>33</sup> The contraction of the scar tissue may pull the shaft into the abdomen, in effect shortening the penis or burying it completely.<sup>34</sup>

- **Circumcision disrupts circulation:**

Circumcision interrupts the normal circulation of blood throughout the penile skin system and glans. The blood flowing into major penile arteries is obstructed by the line of scar tissue at the point of incision, creating backflow instead of feeding the branches and capillary networks beyond the scar. Deprived of blood, the meatus may contract and scarify, obstructing the flow of urine.<sup>35</sup> This condition, known as meatal stenosis, often requires corrective surgery. Meatal stenosis is found almost exclusively among boys who have been circumcised.

Circumcision also severs the lymph vessels, interrupting the circulation of lymph and sometimes causing lymphedema, a painful, disfiguring condition in which the remaining skin of the penis swells with trapped lymph fluid.

- **Circumcision harms the developing brain:**

Recent studies published in leading medical journals have reported that circumcision has long-lasting detrimental effects on the developing brain,<sup>36</sup> adversely altering the brain's perception centers. Circumcised boys have a lower pain threshold than girls or intact boys.<sup>37</sup> Developmental neuropsychologist Dr. James Prescott suggests that circumcision can cause deeper and more disturbing levels of neurological damage, as well.<sup>38, 39</sup>

- **Circumcision is unhealthy and unhygienic:**

One of the most common myths about circumcision is that it makes the penis cleaner and easier to take care of. This is not true. Eyes without eyelids would not be cleaner; neither would a penis without its foreskin. The artificially externalized glans and meatus of the circumcised penis are constantly exposed to abrasion and dirt, making the circumcised penis, in fact, more unclean. The loss of the protective foreskin leaves the urinary tract vulnerable to invasion by bacterial and viral pathogens.

The circumcision wound is larger than most people imagine. It is not just the circular point of union between the outer and inner layers of the remaining skin. Before a baby is circumcised, his foreskin must be torn from his glans, literally skinning it alive. This creates a large open area of raw, bleeding flesh, covered at best with a layer of undeveloped protomucosa. Germs can easily enter the damaged tissue and bloodstream through the raw glans and, even more easily, through the incision itself.

Even after the wound has healed, the externalized glans and meatus are still forced into constant unnatural contact with urine, feces, chemically treated diapers, and other contaminants.

Female partners of circumcised men do not report a lower rate of cervical cancer,<sup>40</sup> nor does circumcision prevent penile cancer.<sup>41</sup> A recent study shows that the penile cancer rate is higher in the US than in Denmark, where circumcision, except among Middle-Eastern immigrant workers, is almost unheard of.<sup>42</sup> Indeed, researchers should investigate the possibility that circumcision has actually increased the rate of these diseases.

Circumcision does not prevent acquisition or transmission of sexually transmitted diseases (STDs). In fact, the US has both the highest percentage of sexually active circumcised males in the Western world and the highest rates of sexually transmitted diseases, including AIDS. Rigorously controlled prospective studies show that circumcised American men are at a greater risk for bacterial and viral STDs, especially gonorrhea,<sup>43</sup> nongonococcal urethritis,<sup>44</sup> human papilloma virus,<sup>45</sup> herpes simplex virus type 2,<sup>46</sup> and chlamydia.<sup>47</sup>

• **Circumcision is always risky:** Circumcision always carries the risk of serious, even tragic, consequences. Its surgical complication rate is one in 500.<sup>48</sup> These complications include uncontrollable bleeding and fatal infections.<sup>49</sup> There are many published case reports of gangrene following circumcision.<sup>50</sup> Pathogenic bacteria such as staphylococcus, Proteus, Pseudomonas, other coliforms, and even tuberculosis can cause infections leading to death.<sup>51, 52</sup> These organisms enter the wound because it provides easy entry, not because the child is predisposed to infection.

Medical journals have published numerous accounts of babies who have had part or all of their glans cut off while they were being circumcised.<sup>53, 54, 55</sup> Other fully conscious, unanesthetized babies have had their entire penis burned off with an electrocautery gun.<sup>56, 57, 58</sup> The September 1989 Journal of Urology published an account of four such cases.<sup>59</sup> The article described the sex-change operation as "feminizing genitoplasty," performed on these babies in an attempt to change them into girls. The March 1997 Archives of Pediatrics and Adolescent Medicine described one young person's horror on learning that "she" had been born a nor-

mal male, but that a circumciser had burned his penis off when he was a baby.<sup>60</sup> Many other similar cases have been documented.<sup>61, 62</sup> Infant circumcision has a reported death rate of one in 500,000.<sup>63, 64</sup>

• **Circumcision harms mothers:** Scientific studies have consistently shown that circumcision disrupts a child's behavioral development. Studies performed at the University of Colorado School of Medicine showed that circumcision is followed by prolonged, unrestful non-REM (rapid-eye-movement) sleep.<sup>65</sup> In response to the lengthy bombardment of their neural pathways with unbearable pain, the circumcised babies withdrew into a kind of semicomatose state that lasted days or even weeks.

Numerous other studies have proven that circumcision disrupts the mother-infant bond during the crucial period after birth. Research has also shown that circumcision disrupts feeding patterns. In a study at the Washington University School of Medicine, most babies would not nurse right after they were circumcised, and those who did would not look into their mothers' eyes.<sup>66</sup>

• **Circumcision violates patients' and human rights:** No one has the right to cut off any part of someone else's genitals without that person's competent, fully informed consent. Since it is the infant who must bear the consequences, circumcision violates his legal rights both to refuse treatment and to seek alternative treatment. In 1995, the American Academy of Pediatrics Committee on Bioethics stated that only a competent patient can give patient consent or informed consent.<sup>67</sup> An infant is obviously too young to consent to anything. He must be protected from anyone who would take advantage of his defenselessness. The concept of informed parental permission allows for medical interventions in situations of clear and immediate medical necessity only, such as disease, trauma, or deformity. The human penis in its normal, uncircumcised state satisfies none of these requirements.

Physicians have a duty to refuse to perform circumcision. They also must educate parents who, out of ignorance or misguidance, request this surgery for their sons. The healthcare professional's obligation is to protect the interests of the child. It is unethical in the extreme to force upon a child an amputation he almost certainly would never have chosen for himself.

## Common Sense

To be intact, as nature intended, is best. The vast majority of males who are given the choice value their wholeness and keep their foreskins, for the same reason they keep their other organs of perception. Parents in Europe and non-Muslim Asia never have forced their boys to be circumcised. It would no more occur to them to cut off part of their boys' penises than it would to cut off part of their ears. Respecting a child's right to keep his genitals intact is normal and natural. It is conservative in the best sense of the word.

A circumcised father who has mixed feelings about his intact newborn son may require gentle, compassionate psychological counseling to help him come to terms with his loss and to overcome his anxieties about normal male genitalia. In such cases, the mother should steadfastly protect her child, inviting her husband to share this protective role and helping him diffuse his negative feelings. Most parents want what is best for their baby. Wise parents listen to their hearts and trust their instinct to protect their baby from harm. The experience of the ages has shown that babies thrive best in a trusting atmosphere of love, gentleness, respect, acceptance, nurturing, and intimacy. Cutting off a baby's foreskin shatters this trust.

Circumcision wounds and harms the baby and the person the baby will become. Parents who respect their son's wholeness are bequeathing to him his birthright – his body, perfect and beautiful in its entirety.

## NOTES

1. T. J. Ritter and G. C. Denniston, *Say No to Circumcision: 40 Compelling Reasons*, 2nd ed. (Aptos, CA: Hourglass, 1996), 6-20.
2. "Incipit Libellus De Ecclesiasticis Disciplinis et Religione Christiana Collectus. Liber II.XC, XCI" in *Patrologiae Cursus Completus*, vol. 132 (Paris: Apud Garnier Fratres, Editores et J. P. Migne Successores, 1880), 301-302.
3. S. Grayzel, *The Church and the Jews in the XIIIth Century*, vol. 2, ed. K. R. Stow (Detroit, MI: Wayne State University Press, 1989), 246-247.
4. See Note 10, 17-40.
5. M. F. Campbell, "The Male Genital Tract and the Female Urethra," in *Urology*, eds. M. F. Campbell and J. H. Harrison, vol. 2, 3rd ed. (Philadelphia: W. B. Saunders, 1970), 1836.
6. See photographic series: J. A. Erickson, "Three Zones of Penile Skin." In M. M. Lander, "The Human Prepuce," in G. C. Denniston and M. F. Milos, eds., *Sexual Mutilations: A Human Tragedy* (New York: Plenum Press, 1997), 79-81.
7. M. Davenport, "Problems with the Penis and Prepuce: Natural History of the Foreskin" (photograph 1), *British Medical Journal* 312 (1996): 299-301.
8. J. Øster, "Further Fate of the Foreskin," *Archives of Disease in Childhood* 43 (1968): 200-203.

9. H. L. Tan, "Foreskin Fallacies and Phimosis," *Annals of the Academy of Medicine, Singapore* 14 (1985): 626-630.
10. F. A. Hodges, "Short History of the Institutionalization of Involuntary Sexual Mutilation in the United States," in G. C. Denniston and M. F. Milos, eds., *Sexual Mutilations: A Human Tragedy* (New York: Plenum Press, 1997), 35.
11. A. B. Hyman and M. H. Brownstein, "Tyson's 'Glands': Ectopic Sebaceous Glands and Papillomatosis Penis," *Archives of Dermatology* 99 (1969): 31-37.
12. A. Ahmed and A. W. Jones, "Apocrine Cystadenoma: A Report of Two Cases Occurring on the Prepuce," *British Journal of Dermatology* 81 (1969): 899-901.
13. G. N. Weiss et al., "The Distribution and Density of Langerhans Cells in the Human Prepuce: Site of a Diminished Immune Response?" *Israel Journal of Medical Sciences* 29 (1993): 42-43.
14. P. J. Flower et al., "An Immunopathologic Study of the Bovine Prepuce," *Veterinary Pathology* 20 (1983):189-202.
15. Z. Halata and B. L. Munger, "The Neuroanatomical Basis for the Protopathic Sensibility of the Human Glans Penis," *Brain Research* 371 (1986): 205-230.
16. J. R. Taylor et al., "The Prepuce: Specialized Mucosa of the Penis and Its Loss to Circumcision," *British Journal of Urology* 77 (1996): 291-295.
17. H. C. Bazett et al., "Depth, Distribution and Probable Identification in the Prepuce of Sensory End-Organs Concerned in Sensations of Temperature and Touch; Thermometric Conductivity," *Archives of Neurology and Psychiatry* 27 (1932): 489-517.
18. D. Ohmori, "Über die Entwicklung der Innervation der Genitalapparate als Peripheren Aufnahmeapparat der Genitalen Reflexe," *Zeitschrift für Anatomie und Entwicklungsgeschichte* 70 (1924): 347-410.
19. A. De Girolamo and A. Cecio, "Contributo alla Conoscenza dell'innervazione Sensitiva del Prepuzio Nell'uomo," *Bollettino della Societa Italiana de Biologia Sperimentale* 44 (1968): 1521-1522.
20. A. S. Dogiel, "Die Nervenendigungen in der Haut der äusseren Genitalorgane des Menschen," *Archiv für Mikroskopische Anatomie* 41 (1893): 585-612.
21. A. Bourlond and R. K. Winkelmann, "L'innervation du Prépuce chez le Nouveau-né," *Archives Belges de Dermatologie et de Syphiligraphie* 21 (1965): 139-153.
22. R. K. Winkelmann, "The Erogenous Zones: Their Nerve Supply and Its Significance," *Proceedings of the Staff Meetings of the Mayo Clinic* 34 (1959): 39-47.
23. R. K. Winkelmann, "The Cutaneous Innervation of Human Newborn Prepuce," *Journal of Investigative Dermatology* 26 (1956): 53-67.
24. R. Hausmann et al., "The Forensic Value of the Immunohistochemical Detection of Oestrogen Receptors in Vaginal Epithelium," *International Journal of Legal Medicine* 109 (1996): 10-30.
25. See Note 12.
26. American Academy of Pediatrics, *Newborns: Care of the Uncircumcised Penis: Guidelines for Parents* (Elk Grove Village, IL: American Academy of Pediatrics, 1994).
27. See Note 1.
28. See Note 1.
29. S. A. Aldeeb Abu-Sahlieh, "Jehovah, His Cousin Allah, and Sexual Mutilations," in *Sexual Mutilations: A Human Tragedy*, eds. G. C. Denniston and M. F. Milos (New York: Plenum Press, 1997), 41-62.
30. National Center for Health Statistics of the United States Department of Health and Human Services, 1994.
31. See Note 17.
32. G. T. Klauber and J. Boyle, "Preputial Skin-Bridging: Complication of Circumcision," *Urology* 3 (1974): 722-723.
33. J. P. Gearhart, "Complications of Pediatric Circumcision," in *Urologic Complications, Medical and Surgical, Adult and Pediatric*, ed. F. F. Marshall (Chicago: Year Book Medical Publishers, 1986), 387-396.
34. R. D. Talarico and J. E. Jasaitis, "Concealed Penis: A Complication of Neonatal Circumcision," *Journal of Urology* 110 (1973): 732-733.
35. R. Persad et al., "Clinical Presentation and Pathophysiology of Meatal Stenosis Following Circumcision," *British Journal of Urology* 75 (1995): 90-91.
36. A. Taddio et al., "Effect of Neonatal Circumcision on Pain Responses during Vaccination in Boys," *Lancet* 345 (1995): 291-292.
37. A. Taddio et al., "Effect of Neonatal Circumcision on Pain Response during Subsequent Routine Vaccination," *Lancet* 349 (1997): 599-603.
38. J. W. Prescott, "Genital Pain vs. Genital Pleasure: Why the One and Not the Other?" *Truth Seeker* 1 (1989): 14-21.
39. R. Goldman, *Circumcision: The Hidden Trauma* (Boston: Vanguard Publications, 1997), 139-175.
40. M. Terris et al., "Relation of Circumcision to Cancer of the Cervix," *American Journal of Obstetrics and Gynecology* 117 (1973): 1056-1065.
41. C. J. Cold et al., "Carcinoma in Situ of the Penis in a 76-Year-Old Circumcised Man," *Journal of Family Practice* 44 (1997): 407-410.
42. M. Frisch et al., "Falling Incidence of Penis Cancer in an Uncircumcised Population (Denmark 1943-90)," *British Medical Journal* 311 (1995): 1471.
43. B. Donovan et al., "Male Circumcision and Common Sexually Transmissible Diseases in a Developed Nation Setting," *Genitourinary Medicine* 70 (1994): 317-320.
44. G. L. Smith et al., "Circumcision as a Risk Factor for Urethritis in Racial Groups," *American Journal of Public Health* 77 (1987): 452-454.
45. L. S. Cook et al., "Clinical Presentation of Genital Warts among Circumcised and Uncircumcised Heterosexual Men Attending an Urban STD Clinic," *Genitourinary Medicine* 69 (1993): 262-264.
46. I. Bassett et al., "Herpes Simplex Virus Type 2 Infection of Heterosexual Men Attending a Sexual Health Centre," *Medical Journal of Australia* 160 (1994): 697-700.
47. E. O. Laumann et al., "Circumcision in the United States: Prevalence, Prophylactic Effects, and Sexual Practice," *Journal of the American Medical Association* 277 (1997): 1052-1057.
48. W. F. Gee and J. S. Ansell, "Neonatal Circumcision: A Ten-Year Overview: With Comparison of the Gomco Clamp and the Plastibell Device," *Pediatrics* 58 (1976): 824-827.
49. G. W. Kaplan, "Complications of Circumcision," *Urologic Clinics of North America* 10 (1983): 543-549.
50. S. J. Sussman et al., "Fournier's Syndrome: Report of Three Cases and Review of the Literature," *American Journal of Diseases of Children* 132 (1978): 1189-1191.
51. B. V. Kirkpatrick and D. V. Eitzman, "Neonatal Septicemia after Circumcision," *Clinical Pediatrics* 13 (1974): 767-768.
52. J. M. Scurlock and P. J. Pemberton, "Neonatal Meningitis and Circumcision," *Medical Journal of Australia* 1 (1977): 332-334.
53. G. R. Gluckman et al., "Newborn Penile Glans Amputation during Circumcision and Successful Reattachment," *Journal of Urology* 153 (1995): 778-779.
54. B. S. Strimling, "Partial Amputation of Glans Penis during Mogen Clamp Circumcision," *Pediatrics* 87 (1996): 906-907.
55. J. Sherman et al., "Circumcision: Successful Glandular Reconstruction and Survival Following Traumatic Amputation," *Journal of Urology* 156 (1996): 842-844.
56. J. R. Sharpe and R. P. Finney, "Electrocautery Circumcision," *Urology* 19 (1982): 228.
57. C. K. Pearlman, "Caution Advised on Electrocautery Circumcisions," *Urology* 19 (1982): 453.
58. C. K. Pearlman, "Reconstruction Following Iatrogenic Burn of the Penis," *Journal of Pediatric Surgery* 11 (1976):121-122.
59. J. P. Gearhart and J. A. Rock, "Total Ablation of the Penis after Circumcision with Electrocautery: A Method of Management and Long-Term Followup," *Journal of Urology* 142 (1989):799-801.
60. M. Diamond and H. K. Sigmundson, "Sex Reassignment at Birth: Long-Term Review and Clinical Implications," *Archives of Pediatrics and Adolescent Medicine* 151 (1997): 298-304.
61. J. Money, "Ablatio Penis: Normal Male Infant Sex-Reassigned as a Girl," *Archives of Sexual Behavior* 4 (1975): 65-71.
62. D. A. Gilbert et al., "Phallic Construction in Prepubertal and Adolescent Boys," *Journal of Urology* 149 (1993): 1521-1526.
63. R. S. Thompson, "Routine Circumcision in the Newborn: An Opposing View," *Journal of Family Practice* 31 (1990): 189-196.
64. T. E. Wiswell, "Circumcision Circumspection," *New England Journal of Medicine* 336 (1997): 1244-1245.
65. R. N. Emde et al., "Stress and Neonatal Sleep," *Psychosomatic Medicine* 33 (1971): 491-497.
66. R. E. Marshall et al., "Circumcision: II. Effects upon Mother-Infant Interaction," *Early Human Development* 7 (1982): 367-374.
67. Committee on Bioethics, "Informed Consent, Parental Permission, and Assent in Pediatric Practice," *Pediatrics* 95 (1995): 314-317.

## FOR MORE INFORMATION

### Organizations

Doctors Opposing Circumcision (DOC) 2442 N.W. Market Street, Suite 42 Seattle, WA 98107 206-368-8358 [faculty.washington.edu/gcd/DOC/](http://faculty.washington.edu/gcd/DOC/)

The National Organization of Circumcision Information Resource Centers (NOCIRC), PO Box 2512 San Anselmo, CA 94979-2512 415-488-9883. [www.nocirc.org](http://www.nocirc.org)

The National Organization to Halt the Abuse and Routine Mutilation of Males (NOHARMM) PO Box 460795 San Francisco, CA 94146-0795 415-826-9351 [www.noharrrm.org](http://www.noharrrm.org)

Nurses for the Rights of the Child, 369 Montezuma, Suite 354 Santa Fe, NM 87501 505-989-7377 [www.cirp.org/nrc](http://www.cirp.org/nrc)

### Books

Available from bookstores, from the publishers, or from NOCIRC.

Bigelow, Jim, PhD. *The Joy of Uncircumcising! Exploring Circumcision: History, Myths, Psychology, Restoration, Sexual Pleasure and Human Rights*. 2nd ed. Aptos, CA: Hourglass, 1995.

Denniston, George C., MD, MPH, and Marilyn Fayre Milos, RN, eds. *Sexual Mutilations: A Human Tragedy*. (Proceedings of the Fourth International Symposium on Sexual Mutilations, Lausanne, Switzerland, 1996). New York: Plenum Press, 1997.

Goldman, Ronald, PhD. *Circumcision: The Hidden Trauma: How an American Cultural Practice Affects Infants and Ultimately Us All*. Boston: Vanguard Publications, 1997.

Goldman, Ronald, PhD. *Questioning Circumcision: A Jewish Perspective*. 2nd ed. Boston: Vanguard Publications, 1997.

O'Mara, Peggy, ed. *Circumcision: The Rest of the Story-A Selection of Articles, Letters, and Resources 1979- 1993*. Santa Fe, NM: Mothering, 1993.

Ritter, Thomas J., MD, and George C. Denniston, MD. *Say No to Circumcision! 40 Compelling Reasons Why You Should Respect His Birthright and Keep Your Son Whole*, 2nd ed. Aptos, CA: Hourglass, 1996.

### **Video**

Whose Body, Whose Rights? Examining the Ethics and the Human Rights Issue of Infant Male Circumcision. Award-winning documentary. 56 min. VHS. Personal use: VideoFinders, 1-800-343-4727

### **Educational facilities**

UC Center for Media and Independent Learning  
2000 Center Street, 4th Floor Berkeley, CA 94704  
510-642-0460. For World Wide Web ordering and preview:  
[www.cirp.org/CIRP/pages/reviews/whosebody/](http://www.cirp.org/CIRP/pages/reviews/whosebody/)

*Please visit [mothering.com](http://mothering.com) for original article and [www.luckystiff.org](http://www.luckystiff.org) for this printable reproduction.*